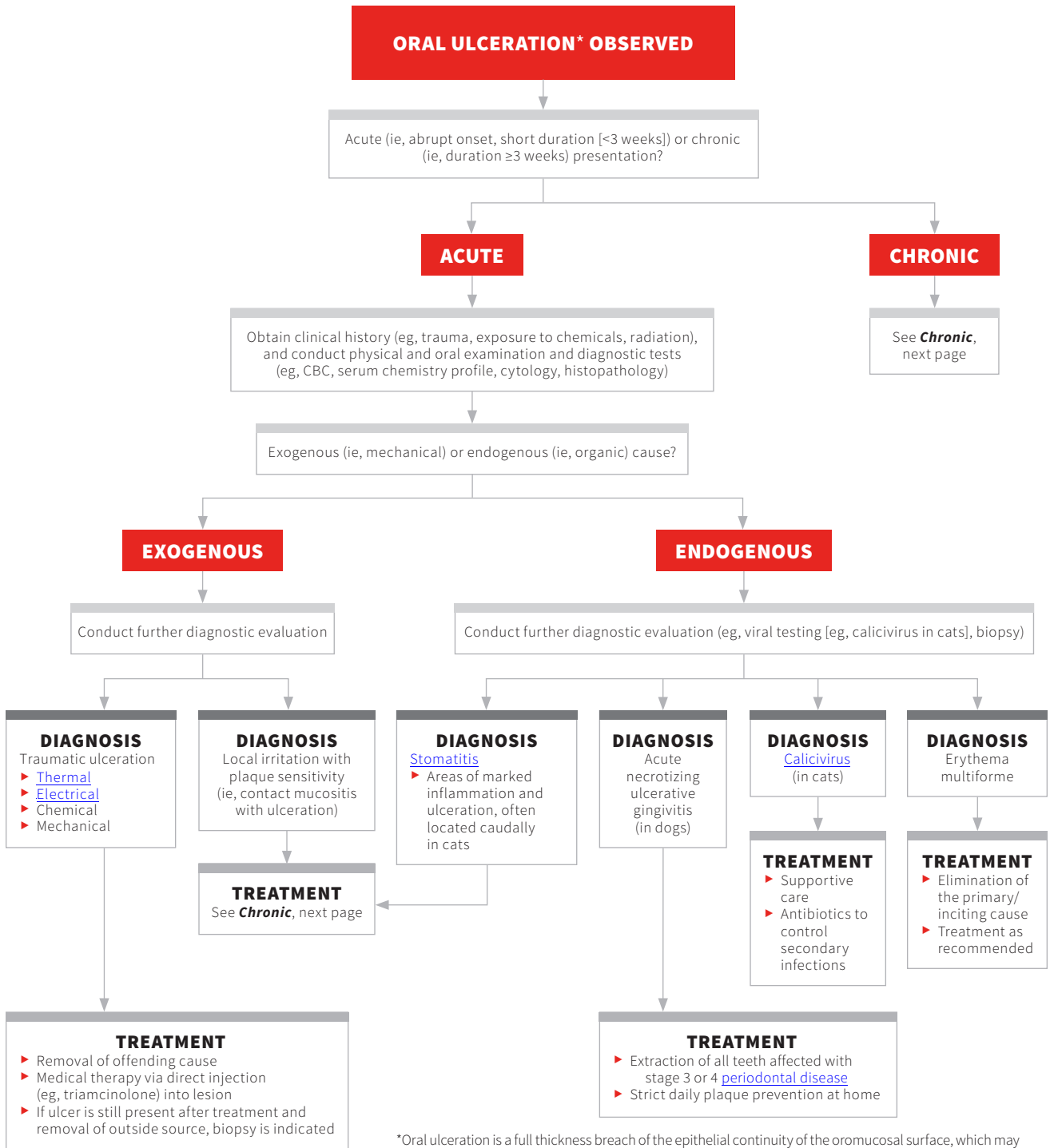


DIAGNOSING ORAL ULCERATION IN DOGS & CATS

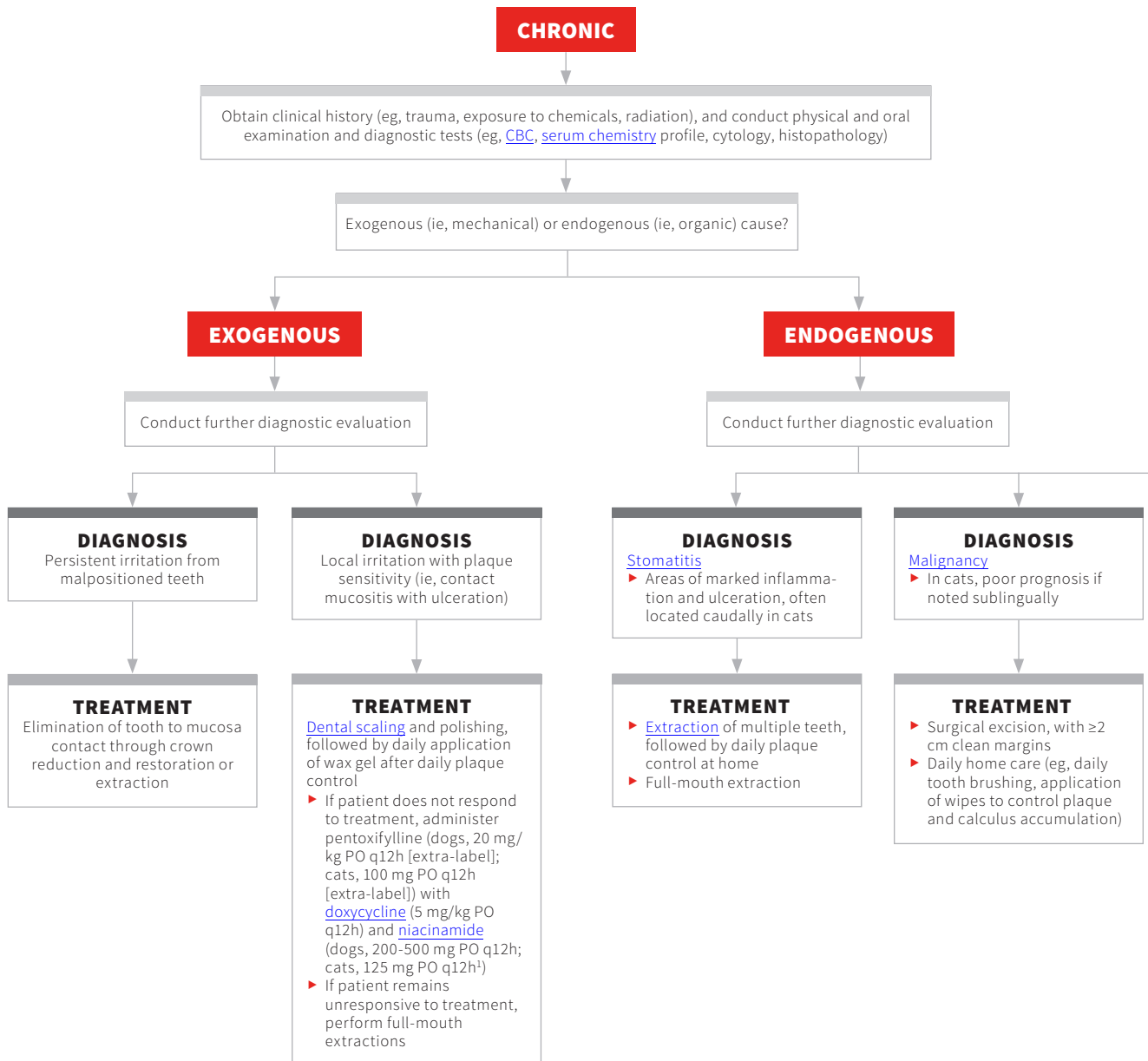
Jan Bellows, DVM, FAVD, DAVDC, DABVP

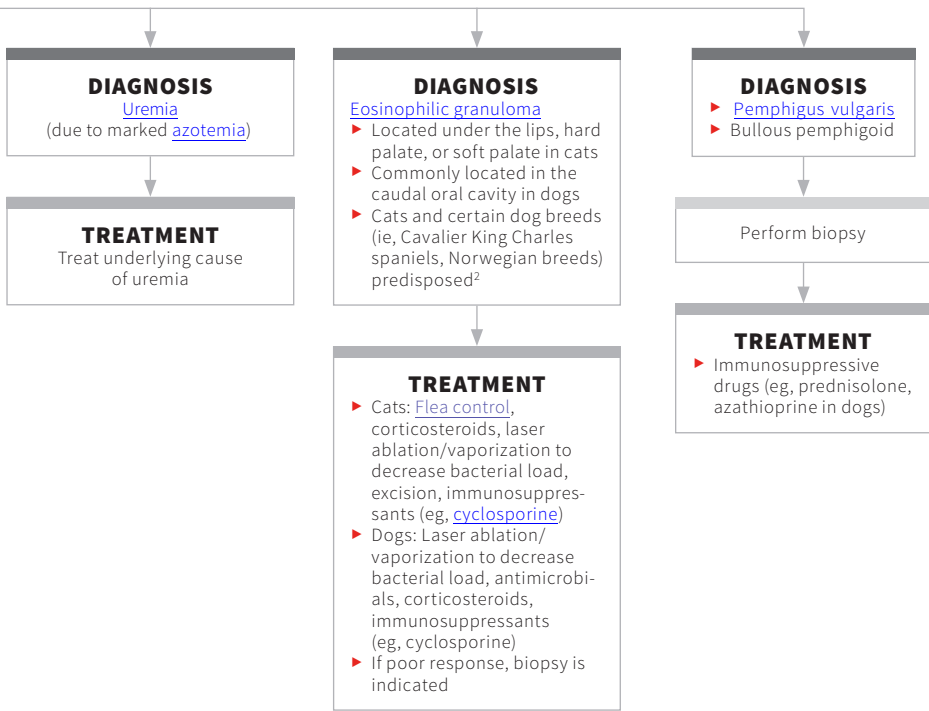
All Pets Dental

Weston, Florida



*Oral ulceration is a full thickness breach of the epithelial continuity of the oromucosal surface, which may extend into the tissues underlying the epithelium, including the submucosa, muscle, and/or periosteum.





References

1. Charlier C. Feline gingivostomatitis: what we know and how we treat it. Paper presented at: CVC East; 2015. http://www.dvm360storage.com/cvc/proceedings/dc/Feline%20Medicine/Charlier/Charlier;%20Cindy_Feline_gingivostomatitis_STYLED.pdf. Accessed December 1, 2018.
2. Bonello D, Roy CG, Verstraete FJM. Non-neoplastic proliferative oral lesions. In: Verstraete FJM, Lommer MJ, eds. *Oral and Maxillofacial Surgery in Dogs and Cats*. Elsevier Saunders; 2012:411-423.

FIND MORE

For an image gallery of various presentations of oral ulceration, see **Oral Ulceration**, page 20.